

Clinical Patient Management System and ERN-EYE: Solving rare eye diseases complex cases

POSTER 212
Theme 6:
The digital health revolution:
hype vs. reality

A. Krucaite^{*1,2}, F. Rotolo¹, L. Mauring^{1,2}, ERN-EYE CPMS health care professional³, D. Leroux¹ and H. Dollfus^{1,2}

¹:ERN-EYE Team, Hôpitaux Universitaires de Strasbourg, Strasbourg, France

²: Centre des Affections Rares en Génétique Ophtalmologique (CARGO), Hôpitaux Universitaires de Strasbourg, Strasbourg, France

³:ERN-EYE Network

Acknowledgement

ERN-EYE is co-funded by the European Union (DG Sante) and by Les Hôpitaux Universitaires de Strasbourg.

Summary

The Clinical Patient Management System (CPMS) is a **secure web-based application** created to facilitate the information exchange between experts of the European Reference Networks for Rare Eye Diseases (ERN-EYE). The **common system** created by the European Commission was secondly **adapted for ERN-EYE** thanks to a **specific dataset for ophthalmological examination**. The aim of this presentation is to show how the CPMS helps to solve unclear clinical cases in three examples.

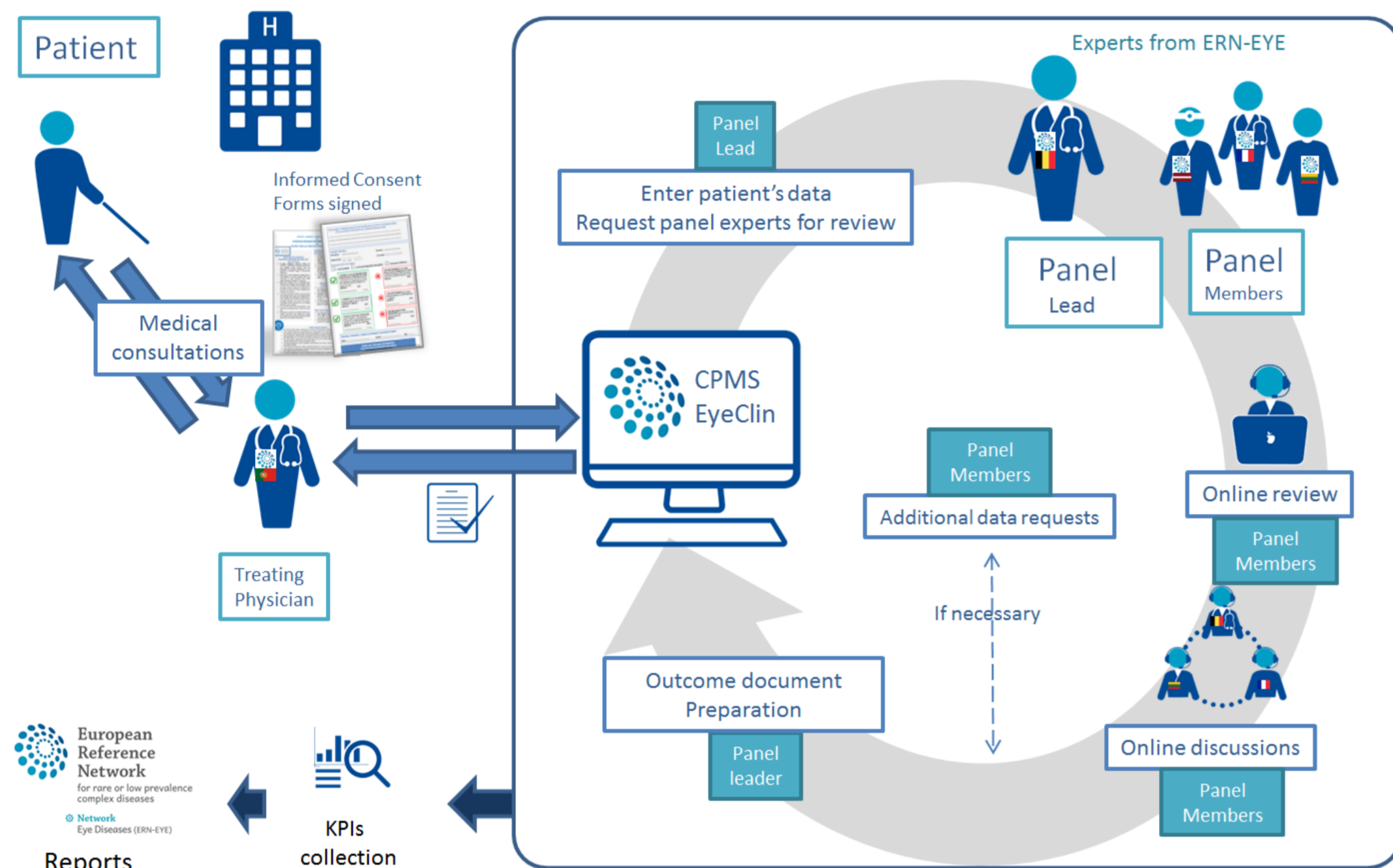


Figure 1: Circuit of case in CPMS

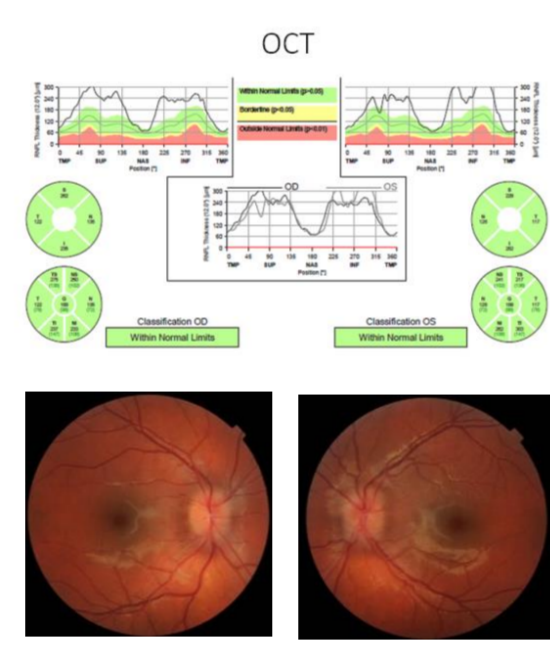
Case circuit within the CPMS (Figure 1)

To get help with managing a specific patient, the clinician has to upload the case using a specifically developed dataset available on the web application that was worked out by the experts in the field. By enrolling a patient on the application, the physician opens a new panel to share the case and is therefore designated as a panel lead. A panel composed of different experts can be invited and each expert gives an opinion on the case based on experts consensus. The application generates an outcome document which constitutes a recommendation for the treating physician.

Three examples of concrete cases solved using the CPMS

1. Using CPMS through comments

- 15-year-old female with bilateral papilledema and ocular pain
- No visual loss
- No signs of intracranial hypertension (IH)
- Carrier of Leber's hereditary optic neuropathy (LHON) mutation
- No signs of acute stage of LHON
- Consultation request:** possible explanation for this papilledema?



Member	Status	Actions
eyehpuser1	Lead	Invited: 12/Mar/2019
testuser		
doctor 11	Invited	Invited: 12/Mar/2019

1 invitations are outstanding

eyehpuser1 testuser
doctor 11 was 12/Mar/2019 11:27 invited to join the panel

Add a comment

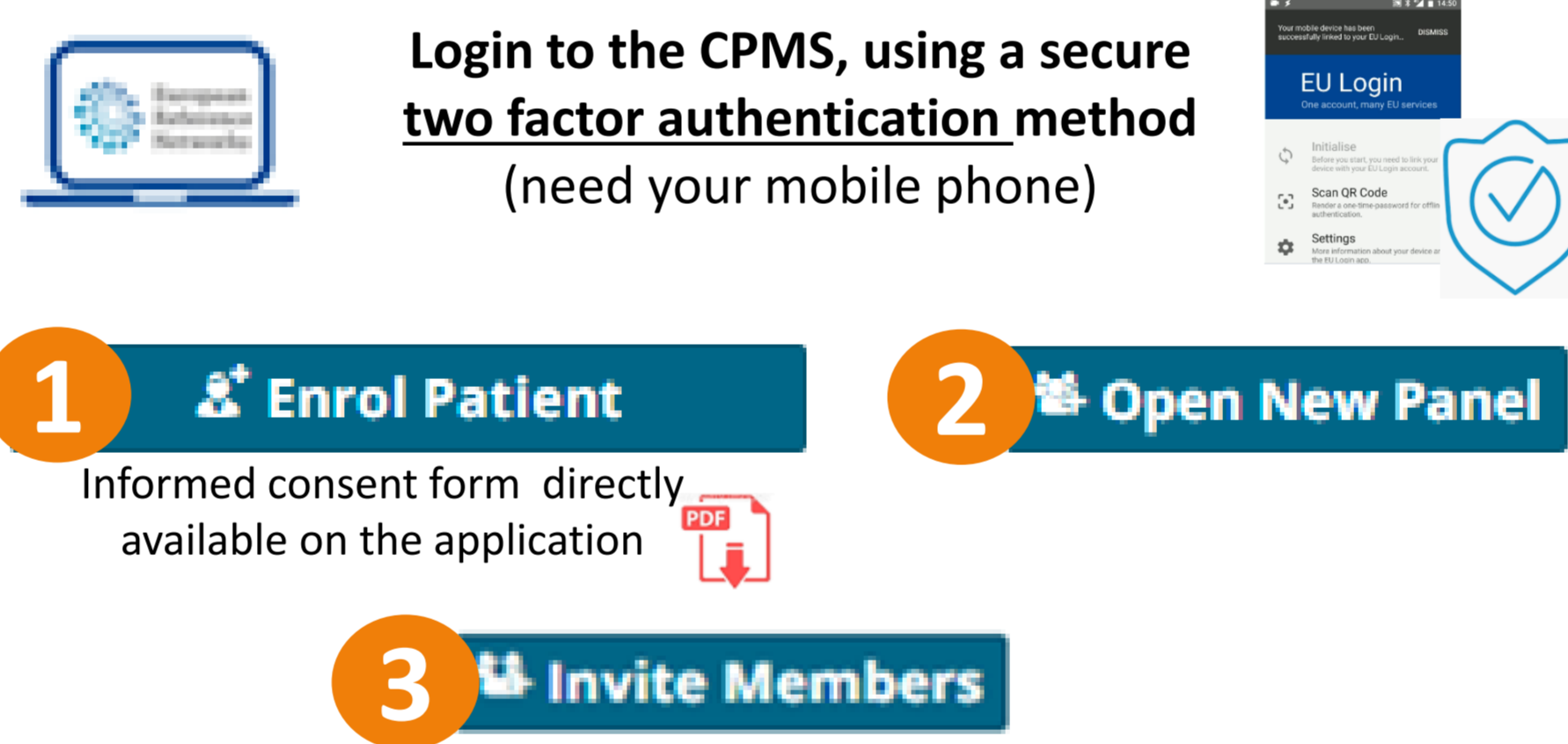
Panel members can write a comment or request additional data

5 experts from 5 countries

Panel lead writes an outcome document

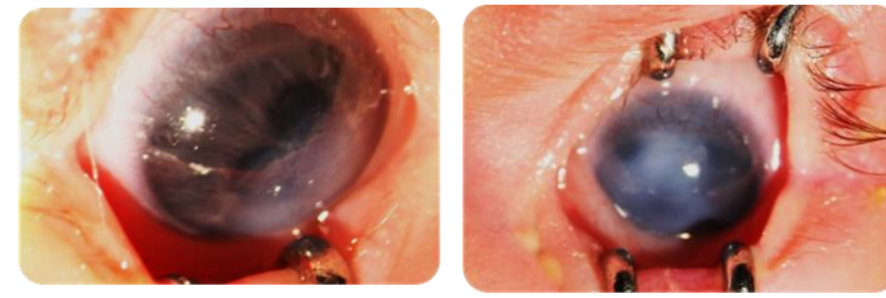
- Asymptomatic carriers of the LHON mutation can have papilledema.
- Detailed evaluation of IH is important for LHON carriers with bilateral papilledema.
- Papilledema in LHON mutation carriers may be a risk factor for visual loss.
- OCT and visual field test may identify LHON carriers at high risk for visual impairment.
- Idebenone therapy should be indicated.

Outcome Document



2. Using CPMS through contributions

- 2-month-old female with nystagmus and Peters anomaly (anterior segment dysgenesis) in both eyes
- Multisystemic malformations
- Consultation request:** recommendations for treatment?



Panel members can write a contribution

Record Contribution

3 experts from 3 countries

Panel lead writes an outcome document

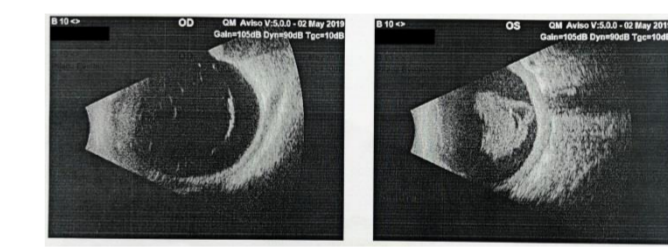
Recommended treatment approach:
surgical optical-sector iridectomy

Outcome Document

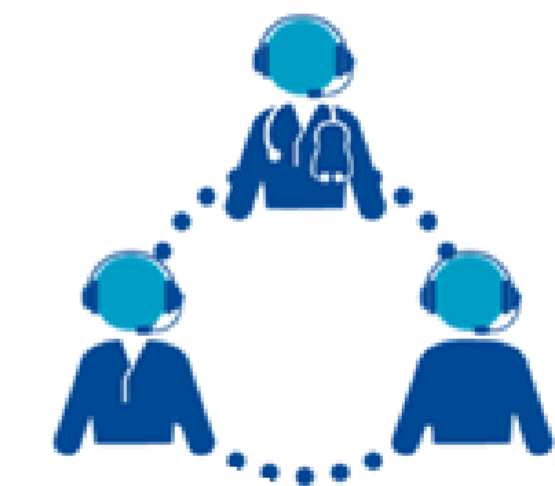

3. Using CPMS through videoconference tool

- 5-year-old female with genetically confirmed Stickler syndrome and significant photophobia
- High myopia and fibrous tissue in vitreous body of the right eye
- Old total retinal detachment, secondary glaucoma and chronic uveitis in the left eye
- Consultation request:** laser preventive treatment for the right eye?



Data protection



Schedule Meeting



Discuss the case by a secure videoconference tool

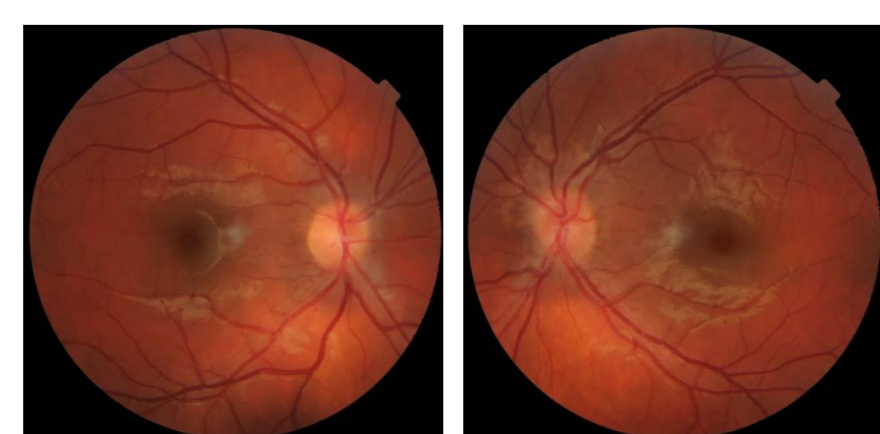
Summary of the meeting

13 experts from 5 countries

- Possible preventive treatment to the right eye:
- Scleral buckling procedure: eye is growing, might provoke anterior segment ischemia.
 - Laser therapy: invasive manipulations might provoke retinal detachment.
 - Frequent follow-ups.**

CLINICAL OUTCOME – Follow-up after CPMS expert review

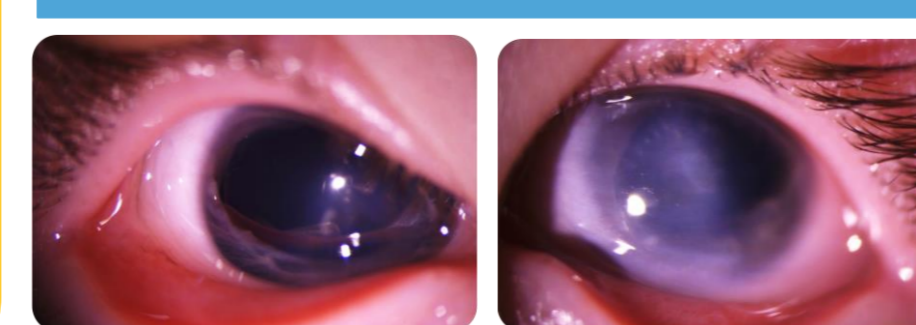
- Papilledema has decreased.
- Visual acuity is stable.
- Patient is under Idebenone therapy.
- Follow-up every 6 months.



After the surgery:

- Right eye follows the light and objects.
- Left eye is deviated inward.
- Small residual horizontal nystagmus.

OUTCOME IN REALITY



- Both eyes were examined under general anesthesia.
- No retinal degenerations and tears in the right eye.
- Case is still active in CPMS because of severe pain and photophobia in the left eye.

Conclusion

Through these three examples the CPMS has shown an **effectiveness to manage difficult cases** affected by rare eye diseases that cause visual impairment in children and young adults. It is the only application in Europe that has the **power of easily accessing experts all over Europe** in the spirit of the leitmotiv "the expertise travels, not the patient". Thanks to this system having an opinion on a complex or rare case abroad has been made accessible both for the patient and the physician.