

# Genetic diagnoses in skeletal ciliopathies using MPS, structural variant, and RNA analyses

Anna Hammarsjö<sup>1</sup>, Maria Pettersson<sup>1</sup>, David Chitayat<sup>2,3</sup>, Atsuhiko Handa<sup>4</sup>, Fulya Taylan<sup>5</sup>, Dominyka Batkovskytė<sup>5</sup>, Britt-Marie Anderlid<sup>1</sup>, Angela E. Lin<sup>6</sup>, Kenji Shimizu<sup>7</sup>, Ana Beleza-Meireles<sup>8,9</sup>, Brian Hon-Yin Chung<sup>10,11</sup>, Ulrika Voss<sup>12</sup>, Ann Nordgren<sup>1</sup>, Gen Nishimura<sup>13</sup>, Anna Lindstrand<sup>1,14</sup>, Giedre Grigelioniene<sup>1,15</sup>

<sup>1</sup>Department of Molecular Medicine and Surgery, <sup>2</sup>Center for Molecular Medicine, Karolinska Institutet and Clinical Genetics, Karolinska University Laboratory, Karolinska University Hospital, Stockholm, Sweden, <sup>3</sup>Division of Clinical and Metabolic Genetics, The Hospital for Sick Children, University of Toronto, Toronto, Ontario, Canada, <sup>4</sup>The Prenatal Diagnosis and Medical Genetics Program, Department of Obstetrics and Gynecology, Mount Sinai Hospital, University of Toronto, Toronto, Ontario, Canada, <sup>5</sup>Department of Radiology, University of Iowa Hospitals and Clinics, Iowa City, IA, USA, <sup>6</sup>Department of Molecular Medicine and Surgery, Karolinska Institutet, Stockholm, Sweden, <sup>7</sup>Medical Genetics, Massachusetts General Hospital for Children, Boston, Massachusetts, USA, <sup>8</sup>Division of Medical Genetics, Saitama Children's Medical Center, Saitama, Japan, <sup>9</sup>Department of Clinical Genetics and Genetics, City of Hengli, Hengli and S. Thomas' 10th Floor, London, United Kingdom, <sup>10</sup>Center for Genomics and Reproductive Biology, King's College London, London, United Kingdom, <sup>11</sup>Department of Pediatrics and Adolescent Medicine, The University of Hong Kong and Shenzhen Hospital, Foshan District, Shenzhen, China, <sup>12</sup>Department of Pediatrics and Adolescent Medicine, Queen Mary Hospital, The University of Hong Kong, Hong Kong, China, <sup>13</sup>Department of Pediatric Radiology, Karolinska University Hospital, Stockholm, Sweden, <sup>14</sup>Department of Pediatric Imaging, Tokyo Women's Children's Medical Center, Tokyo, Japan, <sup>15</sup>These authors contributed equally to this work

## SUMMARY

- High yield (86 %) of genetic diagnoses in 28 probands with skeletal ciliopathies by combination of SNV, CNV, and RNA analyses
- Likely disease-causing variants were detected in *DYNC2H1*, *WDR19*, *C2CD3*, *KIAA0753*, *TTC21B*, *EVC* and *EVC2*
- Synonymous or intronic changes in close vicinity to canonical splice sites can lead to disease phenotype
- We emphasize the role of MPS, in combination with RNA and gene dose analyses, as an efficient way to identify pathogenic variants in genetically heterogeneous but clinically similar disorders like skeletal ciliopathies.

**Keywords:** Skeletal ciliopathy, skeletal dysplasia, silent mutations, cryptic splice site, whole genome sequencing

## BACKGROUND

Cilia are important for cell migration and signaling in development of many organs, including the skeleton. Skeletal ciliopathies are a heterogeneous group of disorders with overlapping features caused by mutations in more than 30 genes coding for different cilia proteins. The most distinctive skeletal features are narrow thorax, short and horizontally oriented ribs, short tubular bones with metaphyseal irregularities, hypoplastic pelvis with characteristic trident acetabulum, and brachydactyly with cone-shaped epiphyses. Massively parallel sequencing (MPS) leads to quick molecular diagnoses when searching for disease-causing variants and discovery of novel genetic causes in human Mendelian disorders.

## Aim of the study

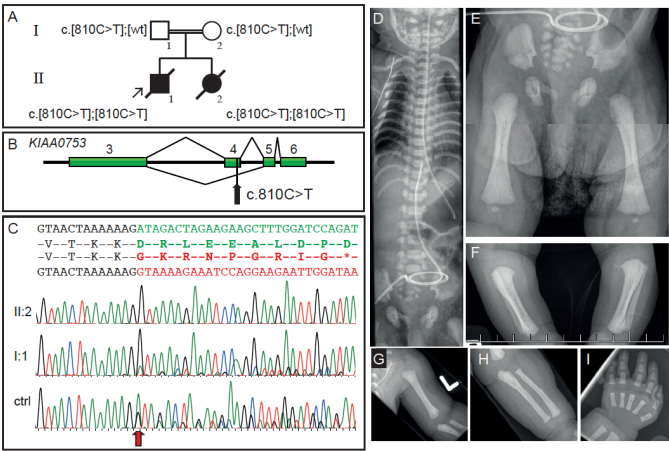
The aim of our study was to extend the genetic spectrum in skeletal ciliopathies via MPS and CNV screening in unrelated individuals with radiological findings of skeletal ciliopathies.

## RESULTS

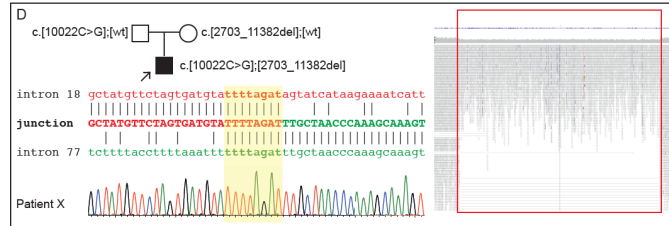
This study included 28 probands with clinical radiographic diagnoses of SRPS/ATD, CED, EVC, and two with unclassifiable skeletal ciliopathies. Pathogenic variants were identified in 86 %, (n=24) of the individuals in *DYNCH2H1*, *WDR19*, *C2CD3*, *KIAA0753*, *TTC21B*, *EVC* and *EVC2* genes, most frequently (46 %) in *DYNC2H1*. Four patients were found to be heterozygous for variants in skeletal ciliopathy genes, however no molecular diagnosis could be established.

Six patients with splice events in this cohort received diagnoses due to RNA analysis. A very rare synonymous variant (c.810C>T) was found in *KIAA0753* and sequencing of cDNA confirmed exon 4 skipping (Fig. 1) in three families. Another patient had a synonymous variant leading to exon skipping in *DYNC2H1*. RNA analysis also revealed two intronic variants in *DYNC2H1* and *EVC* that introduced cryptic splice sites.

Structural variants were detected in two individuals. One patient with a mild skeletal ciliopathy phenotype had a *de novo* 6.7 Mb deletion on chromosome 1 (1q24q25 microdeletion syndrome). Another patient with unclassified skeletal ciliopathy had a missense variant in compound with a 161 kb intragenic deletion in *DYNC2H1* (Fig. 2).



**Fig 1. Molecular and radiographical features of synonymous splice variant in *KIAA0753*.** (A) Pedigree of family and segregation of the variant. (B) Schematic figure of region from exon 3 to exon 6 of *KIAA0753* indicating the normal (top) and abnormal (bottom) splice patterns. (C) cDNA sequences show exon 4 skipping in homozygous state in proband (II:2, red) and in heterozygous state in father (I:1, green). (D-I) X-rays of II:2 at 5 days of age showing narrow thorax, hypoplastic lower pelvis, broad metaphyses in femur, tibia, humerus, ulna, and short metacarpals of the hand



**Fig 2. Intragenic deletion in *DYNC2H1*.** Pedigree of family with intragenic 161 kb deletion and schematic representation of breakpoint junction between intron 18 and intron 77. Highlighted in yellow is the 8 bp microhomology and Sanger sequencing trace from the affected proband over the breakpoint. Reads and coverage from the WGS data show split reads and drop in coverage over the deletion region